

Endovenous Laser Therapy in the Treatment of Lower-limb Venous Ulcers

Terence Kiat Beng Teo, MBBS, FRCR, FAMS, Kiang Hiong Tay, MBBS, FRCR, FAMS, Shueh En Lin, MBBS, FRCR, Seck Guan Tan, MBBS, FRCS, FAMS, Richard H. Lo, MBBS, FRCR, FAMS, Manish Taneja, MBBS, MD, FRCR, Farah G. Irani, MBBS, MD, FRCR, Mathew George Sebastien, MBBS, M.Med, FRCS, Kiat Hon Lim, MBBS, FRCPath, FRCPA, and Bien Soo Tan, MBBS, FRCR, FAMS

PURPOSE: To assess the efficacy of endovenous laser therapy (EVLT) in the treatment of lower-limb venous ulcers secondary to venous reflux.

MATERIALS AND METHODS: Forty-four of 139 patients referred for EVLT from January 2004 to August 2007 had nonhealing venous ulcers. Preprocedural duplex ultrasound (US) was performed to document saphenous venous reflux secondary to saphenofemoral/saphenopopliteal junction incompetence, deep venous insufficiency, and deep vein thrombosis. Follow-up intervals were within 1 week, monthly until ulcer healing, and every 6 months thereafter. Mean follow-up period was 35.8 months (range, 8.1–59.3 months).

RESULTS: Mean great saphenous vein (GSV) diameter and length treated were 9.9 mm (range, 5.5–16.0 mm) and 36.7 cm (range, 20.0–60.0 cm). Mean laser energy used was 3,292 J (range, 1,392–4,971 J). Mean energy deposited per centimeter of vein was 93.6 J/cm (range, 45.2–182.0 J/cm). Mean laser time was 232 seconds (range, 99–347 sec). Fifteen patients with follow-up duplex US had no GSV flow at 6 months, with nonvisualization indicating complete obliteration. Ulcer healing occurred as early as 1 week after the procedure in some patients. Cumulative healing rates at 1, 3, 6, and 12 months were 82.1%, 92.5%, 92.5%, and 97.4%, respectively. No ulcer had recurred at 1 year, but ulcers recurred in five patients at 14, 14, 23, 35, and 52 months after EVLT, respectively. One patient with a nonhealing ulcer 2 years after treatment developed well differentiated squamous cell carcinoma.

CONCLUSIONS: Ulcer epithelization occurred with continued GSV occlusion and loss of flow. Most ulcers healed within 3 months with no recurrence at 1 year. Nonhealing ulcers should undergo biopsy to exclude malignant transformation.

J Vasc Interv Radiol 2010; 21:657–662

Abbreviations: DVT = deep vein thrombosis, EVLT = endovenous laser therapy, GSV = great saphenous vein, SFJ = saphenofemoral junction

LOWER-LIMB chronic venous insufficiency is a common clinical condition that affects 25% of women and 15% of men in the United States (1). If left un-

treated, approximately 50% of patients with significant superficial venous insufficiency will develop chronic symptoms of lower-limb edema, eczema, pigmentation, hemorrhage, and ulceration (2). According to the Clinical, Etiological, Anatomical, Pathophysiological classification of chronic venous disorder, open venous ulceration is of the greatest severity (class 6), and it is estimated to affect 4% of the population older than age 65 years, with a female-to-male ratio of 3:1 (3). Valvular incompetence at the saphenofemoral junction (SFJ) with great saphenous vein (GSV) reflux is the most common cause of chronic venous insufficiency encountered in clinical practice (4).

Conservative medical and surgical

treatment strategies for venous ulcers have been developed. Lower-limb compression is the mainstay of medical treatment. Its goal is to eliminate edema and venous hypertension, hence promoting healing (3,5). Adjunctive conservative measures include appropriate antibiotic therapy for infected ulcers, removal of necrotic tissue, and appropriate primary absorptive wound dressing based on the expected amount of ulcer exudates (5). The principle of surgical treatment is the elimination of venous hypertension secondary to venous reflux. Traditional techniques involve high ligation of the vein at the SFJ with stripping of the GSV or ligation of the saphenopopliteal junction with stripping of the short saphenous vein. Scler-

From the Departments of Diagnostic Radiology (T.K.B.T., K.H.T., S.E.L., R.H.L., M.T., F.G.L., B.S.T.), General Surgery (S.G.T., M.G.S.), and Pathology, (K.H.L.), Singapore General Hospital, Outram Road, 169608 Singapore. Received July 2, 2009; final revision received December 20, 2009; accepted January 4, 2010. Address correspondence to T.K.B.T.; E-mail: tkbteo@yahoo.com.sg

From the SIR 2008 Annual Meeting.

None of the authors have identified a conflict of interest.

© SIR, 2010

DOI: 10.1016/j.jvir.2010.01.029

rotherapy may be performed to create swelling and disruption of endothelial cells, causing occlusion of the incompetent vein. Other described surgical alternatives that are not commonly done in venous practice include application of an external band to restore saphenous competence and the use of skin grafting/free flap in the treatment of recalcitrant ulcers (3,5).

Endovenous laser therapy (EVLT) is an alternative that is minimally invasive compared with surgery for the treatment of GSV reflux, especially in patients who are poor surgical candidates (6). EVLT is performed by gaining access to the saphenous vein, placing an introducer sheath over a wire, introducing the laser fiber through the sheath, applying tumescent anesthetic, and then withdrawing the fiber along the course of the vein. Direct endothelial damage is caused by the laser energy, thereby resulting in collagen contraction, fibrosis, and hyperplasia with subsequent occlusion of the vein (7).

The purpose of this study is to assess the efficacy of EVLT in treating ulcers secondary to venous reflux. This manuscript was prepared in accordance with the *Recommended Reporting Standards for Endovenous Ablation for the Treatment of Venous Insufficiency: Joint Statement of the American Venous Forum and the Society of Interventional Radiology* (8).

MATERIALS AND METHODS

Patient Selection

This institutional review board–approved study was designed as a prospective, nonrandomized, consecutive-enrollment, single-center trial in a tertiary setting. No controls or adjunctive therapy were used. Informed consent was obtained from all patients enrolled via a written informed consent form acknowledging the risks involved and other issues that conform to the standard of care for informed consent practices.

One hundred thirty-nine patients were referred for EVLT from January 2004 to August 2007. Of these, 44 patients (21 men and 23 women) with a mean age of 62.9 years (range, 38–90 y) had nonhealing venous ulcers in one limb and were enrolled in the study. A total of 44 limbs were treated. The majority of the venous ulcers were

over the gaiter's area. Nine patients had previous varicose vein surgical intervention. Pre-EVLT duplex ultrasound (US) was performed in all patients to exclude deep vein thrombosis (DVT), deep venous insufficiency (DVI), and to document saphenous venous reflux secondary to SFJ or SPJ incompetence. Forty-three patients had GSV reflux, 1 patient had SSV reflux, and 11 patients had DVI. Patients who were unable to ambulate or had documented deep vein thrombosis (DVT) in the unilateral lower limb on US, and women who were pregnant, nursing, or planning to become pregnant during the course of the study, were excluded.

Procedure

After informed consent was obtained, the patient was placed on a fluoroscopic table. Preliminary duplex scan of the leg was performed to confirm GSV reflux and exclude DVT. The patient's medial lower thigh was then prepared and draped in the usual sterile fashion. After local anesthesia with 1% lignocaine HCl (Pfizer, Bentley, Australia), the most distal GSV at the level of the knee was accessed with use of a 4-F micropuncture set (Cook, Bloomington, Indiana) under hand-held US guidance. A 5-F, 450-mm sheath (Diomed, Cambridge, United Kingdom) was advanced over a 0.035-inch J-shaped Teflon guide wire (Diomed) through the GSV with the tip of the sheath placed approximately 1.5 cm from the SFJ. A venogram was performed and the position of the sheath confirmed with injection of a small amount of contrast under fluoroscopy as well as with US. Subsequently, a 600- μ m bare-tip laser fiber (Diomed) was advanced through the sheath with the tip of the laser fiber placed approximately 1.5 cm distal to and away from the SFJ by retracting the sheath over the fiber by 2 cm as indicated by the markings on the laser fiber. Final position of the laser tip is confirmed with US.

The tumescent anesthetic solution of 0.1% lignocaine HCl was prepared by diluting 50 mL of 1% lignocaine HCl with 450 mL of normal saline solution. One hundred to 200 mL of the tumescent anesthetic solution was injected over the entire length of the GSV under real-time sonographic guidance

with use of a 19.5-gauge Uni-Dwell needle (Angiomed, Karlsruhe, Germany). Attention was paid to the injection of tumescent anesthetic agent in the perivenous space to ensure uniform circumferential collapse of the vein around the laser fiber for maximal vein wall contact with the laser fiber for optimal laser ablation of the venous endothelium. Tumescent anesthesia also helps in providing local pain relief and acts as a "heat sink" and reduces the likelihood of perivenous tissue damage, neural damage, or skin burn from laser heat energy (6). The entire length of GSV was then ablated with the 980-nm diode laser.

For all patients, the power was set at 14 W and the laser ran in continuous mode. The laser fiber pullback speed was kept at approximately 2 mm/sec with the measured markers on the sheath used as a guide. Manual compression was applied over the treated site during the laser pullback to help maximize vein wall contact with the laser fiber.

After treatment, hemostasis at the venous access site was achieved by manual compression. All patients received DuoDERM dressing (Convatec, New Jersey) as standard dressing for the venous ulcers. Thick absorbent pads (Smith & Nephew 9cm x 20cm Combine Dressing) were applied along the length of the treated GSV and over the avulsion sites, followed by a layer of cotton wool wrap (Softban Plus, BSN Medical, Brierfield, England) from ankle to groin. Constant pressure bandage was applied to the treated leg by using Coban self adherent wrap (3M Healthcare, St. Paul, Minnesota) from below the ankle to just below the groin. The pressure bandage was worn 24 hours a day until the first outpatient follow-up visit in 3 to 5 days (depending on appointment dates). This pressure bandage is removed at the first follow-up visit. No graded compression stocking or 4-layer dressing was applied after removal of the pressure bandage. After the procedure, patients were encouraged to ambulate immediately and to keep the treated leg above waist level when sitting or lying down. Patients were also prescribed with two weeks of Celecoxib (Celebrex, Pfizer) of 200 mg daily for 2 weeks if there were no contraindications.

Follow-up

The patients were scheduled for outpatient review within one week, then monthly until the ulcers healed, and thereafter at 6-month intervals. The pressure bandage was removed at the first outpatient review for visual assessment of the venous ulcers. The mean follow-up period was 35.8 months (range, 8.1–59.3 mo). Duplex US was performed at 1 week and 1, 3, and 6 months in some patients to document occlusion of the treated GSV, the presence of any residual reflux, or complication of DVT.

Study Endpoints

The primary endpoint of the study was the assessment of technical and treatment success. Technical success was defined as the feasibility of GSV cannulation and completion of GSV endovenous laser ablation. Treatment success was defined as complete epithelization of the venous ulcer on outpatient follow-up. Treatment failure was defined as failure of complete epithelization after 12-month follow-up.

The secondary endpoints were measurement of the treatment parameters and assessment of complications. Unit energy delivered during treatment was determined by recording the GSV diameter and treated length, total energy delivered, and total laser ablation time. Energy in joules per length of GSV in centimeters was calculated for each patient and reported as mean values and ranges. Complications were assessed as minor and major; minor complications were defined as temporary and self-limiting symptoms without any clinical sequelae and major complications were defined as those requiring further intervention or hospitalization or resulting in permanent sequelae (9).

RESULTS

A total of 44 limbs from 44 individual patients were available for analysis. Concurrent symptoms and comorbidities are summarized in **Tables 1 and 2**, respectively.

EVLT was successfully performed in all patients, yielding a technical success rate of 100%.

The mean GSV diameter and length treated were 9.9 mm (range, 5.5–16.0

Table 1
Concurrent Symptoms (N = 44)

Symptom	No. of Pts.
Varicose veins	36
Leg pain or cramps	33
Pigmentation	30
Ankle edema	23
Bleeding	1
Recurrent cellulites	1

Table 2
Comorbidities (N = 44)

Comorbidity	No. of Pts.
Hypertension	23
Diabetes mellitus	9
Colon cancer	2
Ischemic heart disease	1
Asthma	1
Pulmonary embolism	1

mm) and 36.7 cm (range, 20.0–60.0 cm), respectively. The mean laser energy used was 3,292 J (range, 1,392–4,971 J) and the mean energy deposited per centimeter of vein was 93.6 J/cm (range, 45.2–182.0 J/cm). The mean laser time was 232 seconds (range, 99–347 sec).

Fifteen patients underwent follow-up duplex US. Eight patients were scanned at 1 week, 10 at 1 month, nine at 3 months, and two at 6 months. Among the nine patients scanned at 3 months, the GSV was not visualized in four. At 6 months, the GSV in both patients scanned was also not visualized. In patients with the GSV still visualized, no flow was seen.

Ulcer healing occurred as early as 1 week after the procedure. The cumulative rates of healing at 1, 3, 6 and 12 months were 82.1% ($n = 32$), 92.3% ($n = 36$), 92.3% ($n = 36$), and 97.4% ($n = 38$), respectively (**Fig 1**). Of the 11 patients (11/44, 25%) with concomitant DVI, 10 (10/11, 90.9%) demonstrated ulcer healing within 3 months. There was no recurrence of venous ulcers at the end of the first year of follow up. However, ulcers recurred in 5 patients at 14 (for 2 patients), 23, 35, and 52 months post EVLT (5/44, 11.4%).

Minor complications of ecchymosis, transient tightness, and pain were noted in all patients. These resolved with conservative and symptomatic

treatment. There were no major complications.

DISCUSSION

Conservative treatment with compression therapy has traditionally been the first line of treatment in venous ulcers. The most important factor in the success of any compression technique is the consistency of its application throughout the duration of therapy (4). However, patient compliance remains a limiting factor, as this form of treatment is restrictive and inconvenient. Intolerance may be seen in hypersensitive areas adjacent to a venous ulcer, and difficulty may be experienced in the application of the stockings in elderly patients with limited dexterity (10). Compression may also potentially exacerbate arterial insufficiency (3). The use of modern complex wound dressings has been shown to be superior to adequate compression with simple wound dressing in improving the proportion of healed ulcers as well as the time to ulcer healing (11).

The standard surgical treatment of lower-limb venous reflux has been high ligation with stripping of the vein to the level of the knee and phlebectomies (12). However, surgery is invasive and associated with morbidity, including wound infection, recurrence, saphenous nerve injury, and DVT (12–15).

A randomized study comparing the efficacy of conservative and surgical treatment at one year was performed by Barwell et al (16). They compared saphenous stripping with compression versus compression alone for the healing and prevention of venous leg ulcers in patients with active or healed ulcers. There was no significant difference in the rate of ulcer healing of 65% at 24 weeks. However, significantly fewer patients in the surgical treatment arm experienced recurrent ulceration (12%) compared with the compression alone group (28%) at 12 months. An update of this study by Gohel et al showed no significant difference in the healing rate of 93% for the surgical treatment arm and 89% for the compression alone group at 3 years, but there was statistical significance in the recurrence rate at 4 years of 31% for the surgical arm and 56% for the compression alone group (17). Therefore, sur-

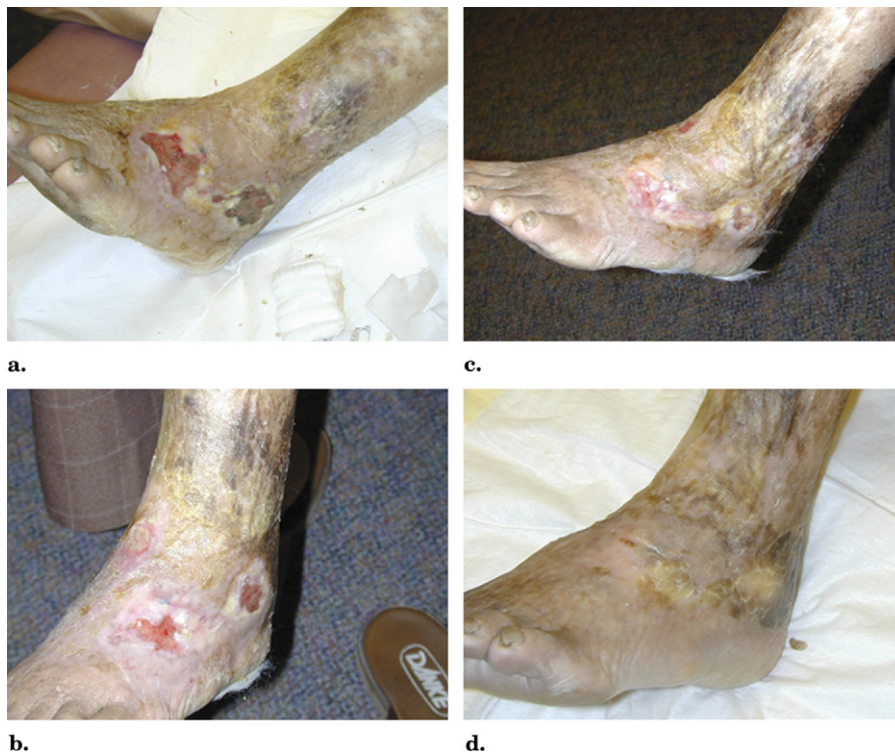

Figure 1. Photographs show healing of venous ulcer by 3 months. Images obtained before EVLT (a), 1 week after EVLT (b), 1 month after EVLT (c), and 3 months after EVLT (d).

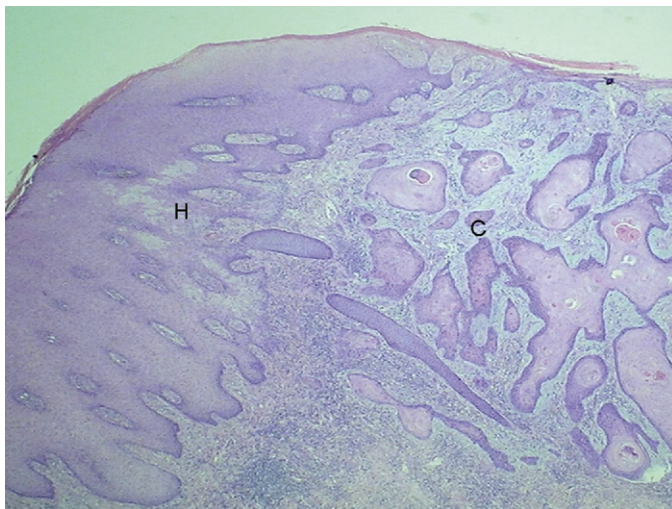


Figure 2. On histologic examination, the left side of the specimen (H) shows hyperplastic squamous epithelium and irregular nest of a well differentiated squamous cell carcinoma (C) on the right. (Hematoxylin and eosin stain, original magnification $\times 20$.)

gical venous intervention will be appropriate to reduce the incidence of ulcer recurrence whenever superficial venous reflux is a prominent component of the disease, but it should not be recommended if acceleration of wound healing is the desired goal (5).

EVLT offers a minimally invasive

alternative to surgery. In a randomized controlled trial comparing EVLT of the GSV versus surgical high ligation and stripping (18), there were no significant differences in safety and efficacy in eliminating GSV reflux, alleviation of symptoms and signs of GSV varicosities, or improvement of qual-

ity of life in the first 6 months after either treatment. However, patients in the surgical group experienced a slight increase in postoperative pain and bruising. Another 2-year clinical study (19) showed that EVLT is at least equal to ligation and stripping, with the vast majority of the treated GSV remaining permanently closed and undergoing shrinkage over time. There were similar rates of recurrence and neovascularization between the two treatment arms, although improved quality of life persisted in the EVLT group.

We did not apply compression therapy (eg, four-layer bandaging or graduated compression stockings) after the initial pressure bandage applied after EVLT was removed 3 to 5 days later. As part of our study, we were evaluating venous ulcer healing rates without the use of compression therapy after obliteration of venous reflux. None of these ulcers increased in size without compression therapy after EVLT and we were still able to achieve venous ulcer healing in 92.3% of patients within 3 months and 97.4% at 12 months. Our findings are comparable to Sharif et al's study of 23 limbs with cumulative healing rates of 87% at 3 months and 100% at 12 months (10). This is a big boon for patients especially in tropical Singapore, where compression garments are uncomfortable because of heat and perspiration and because patients need to frequently visit the hospital for a dressing change. Neglen et al (20) suggest that most venous ulcers that can potentially heal will do so by 6 months after treatment, and recurrence is rare if there has been complete epithelization. Deep venous insufficiency was documented in 25% ($n = 11$) of the 44 patients. At 3 months, 90.9% of these patients ($n = 10$) had ulcer healing with no recurrence during follow up. Hence, the presence of DVI does not appear to affect the rate of ulcer healing or recurrence in our group of patients.

The only patient with a nonhealing venous ulcer at the end of 12 months also had concomitant DVI. He was lost to follow up after 1 year but presented 2 years after the EVLT treatment with the same problem. Biopsy showed well differentiated squamous cell carcinoma (Fig 2). This was excised with skin grafting but recurred 11 months later, requiring further surgery. While

our ulcer healing rates are favorable compared to compression alone or compression combined with surgical stripping of the saphenous vein, we are not entirely clear on the reason for this. We postulate that our favorable results may be due to small ulcer size in our patient population. In addition, we believe that without the use of four-layer dressing our patients were able to have their ulcers dressed daily rather than weekly in patients with four-layer dressing. Frequent dressing changes may have enhanced ulcer healing in our patients (11). Although it may be postulated that our low rate of concomitant DVI may have contributed to our favorable ulcer healing rates, our analysis does not suggest any delay in ulcer healing rates in these patients.

No ulcer recurrence in the first year of follow-up was detected. This is also similar to Sharif et al's findings (10). However, ulcers did recur in 5 of our patients at 14, 14, 23, 35 and 52 months after EVLT treatment. Duplex ultrasound in the patient with a recurrent ulcer at 23 months found that the GSV remained occluded but he had developed DVI in the interim. The patient with a recurrent ulcer at 52 months developed DVT 6 months prior to ulcer recurrence, and we believe that this was the sequelae of post-thrombotic syndrome. No duplex US was performed in the other 3 patients. The ulcers in all 5 patients healed with four-layer dressing. In Sharif et al's study, there was one case of recurrence at 22 months secondary to mid-calf perforator incompetence with a recanalized GSV (10).

Our recurrence rate of 6.8% ($n = 3$), 9.1% ($n = 4$), and 11.4% ($n = 5$) at 2, 3, and 5-year follow-up, respectively, compares favorably with the ESCHAR trial comparing compression alone against compression with surgical saphenous vein stripping (56% and 31%, respectively, at 4 years) (17). Our recurrence rate of 6.8% at 2 years also corresponds closely to that of GSV reflux recurrence of less than 7% at 2 years of follow up by Min et al (6).

The reason for our low rate of ulcer recurrence is also not completely clear. We postulate that our patient population was a very selected one, with the main cause of CVI being GSV reflux. Hence, we believe that as long as the GSV remained ablated and occluded,

then the ulcer recurrence rate would correspondingly be low. Although concomitant DVI may potentially cause ulcer recurrence, all 5 patients with a recurrent ulcer did not have this condition on the pre-EVLT duplex US. Hence, we do not think that pre-EVLT treatment DVI is a predictor of ulcer recurrence.

Common local postoperative complications include ecchymosis, tightness, hypersensitivity along the treated area, or pain and transient paresthesia (21). All of our patients experienced similar signs and symptoms to varying degrees when reviewed on follow-up. However, they were treated conservatively and symptomatically with nonsteroidal anti-inflammatory medication. No major complications were documented.

We started our EVLT service in January 2004. As part of a research protocol to evaluate the efficacy of EVLT in occluding the saphenous veins, we performed serial duplex US examinations at 1 week, 1 month, 3 months, 6 months, and 12 months after EVLT in our first 30 patients. The results in these 30 patients showed a 96.7% incidence of GSV occlusion at 1 week; these veins remained occluded at 6 months and there was one case of GSV recanalization at 3 months. Based on these findings, serial follow-up duplex US scans were discontinued and subsequent patients were assessed clinically with US studies selectively performed in patients with suboptimal clinical outcome. Ten of the 44 patients with venous ulcers belong to this initial cohort of 30 patients in whom serial duplex US scans were performed. The majority of the remaining patients did not have duplex US follow-up as their ulcers were healing well. This is the reason for the low 38.5% rate of follow-up duplex US in our study. Interestingly, our follow-up US studies showed that the effect of venous thermal injury resulted in ongoing obliteration of the targeted vein. At 3 months, duplex US showed nonvisualization of the GSV in four of nine patients. No flow was seen in the other five patients. Repeat duplex US assessment at 6 months in two of these five patients also showed nonvisualization of the GSV. When we first started our EVLT service, there was no evidence that it can replace surgery as the standard of care. Hence, only symptomatic patients (ie, with leg pain or venous ulcers) who were unsuit-

able for surgery or anesthesia were referred for EVLT. This accounts for the unusually high proportion of venous ulcer in our cohort of 139 patients (44 patients, 31.6%).

The range of energy deposited per cm of vein in our study is from 45.2 J/cm to 182 J/cm. This wide range occurred because while gaining experience in the early days of our EVLT service, we pulled back the laser at a faster rate in the belief that this would reduce skin burning. However, as evidence emerged that higher energy deposition resulted in more effective venous ablation, we slowed down the pull back rate (22). Currently, we only pulled back the laser fiber when bubbling was demonstrated at the tip under US. As charring occurred at the laser tip as it was withdrawn, bubbles took longer to form due to impaired heat transmission. Hence, we tended to dwell the laser tip for a longer period closer to the incision site.

The limitations of the present study include the small number of study participants and lack of objective ulcer area measurement. It would be informative if the ulcerated area was measured before intervention and similarly measured in the outpatient clinic on follow-up. This can be done by counting squares on a standardized grid.

To the best of our knowledge, this is the largest series to date studying the use of EVLT solely for the treatment of lower-limb venous ulcers secondary to saphenous vein reflux. EVLT is a safe and efficacious therapy for lower-limb venous ulcers secondary to saphenous vein reflux and may provide an alternative to long-term compression therapy or surgery. It overcomes the inherent difficulty in patient compliance with compression therapy, which is key to treatment success. It is also suitable for elderly and infirm patients who are poor surgical candidates as EVLT may be performed in an outpatient setting with only the use of local anesthesia and without the need for prolonged immobilization. Clinical improvement and ulcer epithelization occur in tandem with continued GSV occlusion and loss of flow, occurring as soon as 1 week after EVLT. Most ulcers that can potentially heal will do so by 6 months, and non-healing ulcers should undergo biopsy to exclude malignant transformation.

References

1. Callam MJ. Epidemiology of varicose veins. *Br J Surg* 1994; 81:167-173.
2. Widmer LK, Mall TH, Martin H. Epidemiology and social medical importance of diseases of the veins. *Munch Med Wochenschr* 1974; 116: 1421-1426.
3. Patel NP, Labropoulos N, Pappas PJ. Current management of venous ulceration. *Plast Reconstr Surg* 2006; 117 (Suppl):S254-S260.
4. Labropoulos N, Giannoukas AD, Delis K, et al. Where does venous reflux start? *J Vasc Surg* 1997; 26:736-742.
5. Marston W. Evaluation and treatment of leg ulcers associated with chronic venous insufficiency. *Clin Plast Surg* 2007; 34:717-730.
6. Min RJ, Khilnani N, Zimmer SE. Endovenous laser treatment of saphenous vein reflux: long term results. *J Vasc Interv Radiol* 2003; 14:991-996.
7. Huang Y, Jiang M, Li W, Lu Z, Huang X, Lu M. Endovenous laser treatment combined with a surgical strategy for treatment of venous insufficiency in lower extremity: a report of 208 cases. *J Vasc Surg* 2005; 42:494-501.
8. Kundu S, Lurie F, Millward SF, et al. Recommended reporting standards for endovenous ablation for the treatment of venous insufficiency: joint statement of the American Venous Forum and the Society of Interventional Radiology. *J Vasc Interv Radiol* 2007; 18:1073-1080.
9. Omary RA, Bettmann MA, Cardella JF, et al. Quality improvement guidelines for the reporting and archiving of interventional radiology procedures. *J Vasc Interv Radiol* 2003; 14(Suppl): S293-S295.
10. Sharif MA, Lau LL, Lee B, Hannon RJ, Soong CV. Role of endovenous laser treatment in the management of chronic venous insufficiency. *Ann Vasc Surg* 2007; 21:551-555.
11. Durkin MT, Turton EP, Scott DJ, Bertridge DC. A prospective randomized trial of Pin versus conventional stripping in varicose vein surgery. *Ann R Coll Surg Engl* 1999; 81:171-174.
12. Critchley G, Handa A, Maw A, Harvey A, Harvey M, Corbett C. Complications of varicose vein surgery. *Ann R Coll Surg Engl* 1997; 79:105-110.
13. Winterborn RJ, Foy C, Earnshaw JJ. Causes of varicose vein recurrence: late results of a randomized controlled trial of stripping the long saphenous vein. *J Vasc Surg* 2004; 40:634-639.
14. Holmes JB, Skajaa K, Holme K. Incidence of lesions of the saphenous nerve after partial or complete stripping of the long saphenous vein. *Acta Chir Scand* 1990; 156:145-148.
15. van Rij AM, Jones GT, Hill GB, et al. Neovascularization and recurrent varicose veins: more histologic and ultrasound evidence. *J Vasc Surg* 2004; 40: 296-302.
16. Barwell JR, Davies CE, Deacon J, et al. Comparison of surgery and compression with compression alone in chronic venous ulceration (ESCHAR study): randomized controlled trial. *Lancet* 2004; 363:1854-1859.
17. Gohel MS, Barwell JR, Taylor M, et al. Long term results of compression therapy alone versus compression plus surgery in chronic venous ulceration (ESCHAR): randomised controlled trial. *BMJ* 2007; 335:83-87.
18. Rasmussen LH, Bjoern L, Lawaetz M, Blemings A, Lawaetz B, Eklof B. Randomized trial comparing endovenous laser ablation of the great saphenous vein with high ligation and stripping in patients with varicose veins: short-term results. *J Vasc Surg* 2007; 46:308-315.
19. Lurie F, Creton D, Eklof B, et al. Prospective randomized study of endovenous radiofrequency obliteration (closure) versus ligation and vein stripping (EVOLVEs): two-year follow-up. *Eur J Vasc Endovasc Surg* 2005; 29:67-73.
20. Neglen P, Hollis KC, Raju S. Combined saphenous ablation and iliac stent placement for complex severe chronic venous disease. *J Vasc Surg* 2006; 44:828-833.
21. Kim HS, Nwankwo IJ, Hong K, EcElgunn PSJ. Lower energy endovenous laser ablation of the great saphenous vein with 980 nm diode laser in continuous mode. *Cardiovasc Intervent Radiol* 2006; 29:64-69.
22. Timperman PE, Sichlau M, Ryu RK. Greater energy delivery improves treatment success of endovenous laser treatment of incompetent saphenous veins. *J Vasc Interv Radiol* 2004; 15:1061-1063.